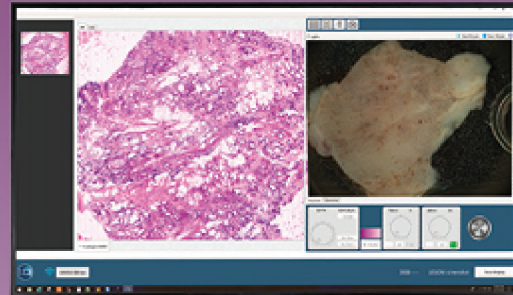


Impressive publications

VivaScope 2500M



VivaScope 2500M

Take a closer look in your special field:

Dermatology	Page 2 - 5
Urology	Page 6 - 9
Gastroenterology	Page 10
Multiple	Page 11
All publications	

Dermatology > Skin

Revolution in fast pathology in dermatology

Application	Review
Study design	A comprehensive review of 79 publications
Microscope generation	G4-G3
Clinical partner (principal investigator)	Dept. of Dermatology, Hospital Clinic of Barcelona, IDIBAPS, University of Barcelona, Barcelona, Spain (Dr. S. Puig & Dr. J. Malvehy)


[CLICK HERE](#)

 PMID: 32134506
(2020)

96.5% specificity and 73.6% sensitivity

Application	BCC margin control
Study design	101 BCCs 78 patients
Microscope generation	G4
Clinical partner (principal investigator)	Dept. of Dermatology, Venereology and Allergology, University Hospital Leipzig AoER, Leipzig, Germany (Dr. S. Grunewald)


[CLICK HERE](#)

 PMID: 33768732
(2021)

91% specificity and 92% sensitivity

Application	BBC margin control
Study design	46 frozen sections of BCCs
Microscope generation	G4
Clinical partner (principal investigator)	Dept. of Dermatology and Allergy, University Hospital, LMU Munich, Munich, Germany (Dr. Hartmann)


[CLICK HERE](#)

 PMID: 33991061
(2021)

92.3% specificity and 96.3% sensitivity

Application	Oral leukoplakia
Study design	27 oral lesions 22 patients
Microscope generation	G4
Clinical partner (principal investigator)	Dept. of Oral and Maxillofacial Surgery, University Hospital Heidelberg, Heidelberg, Germany (Dr. V. Shavlokhova)


[CLICK HERE](#)

 PMID: 34073373
(2021)

High potential in rapid diagnosis and evaluation of the fresh excised OSCCs

Application	Oral squamous cell carcinomas (OSCCs)
Study design	38 OSCCs 35 patients
Microscope generation	G4
Clinical partner (principal investigator)	Dept. of Oral and Maxillofacial Surgery, University Hospital Heidelberg, Heidelberg, Germany (Dr. V. Shavlokhova)


[CLICK HERE](#)

 PMID: 33368199
(2021)

95% specificity and 99% sensitivity

Application	Oral squamous cell carcinomas (OSCCs)
Study design	70 oral lesions 70 patients
Microscope generation	G4
Clinical partner (principal investigator)	Dept. of Oral and Maxillofacial Surgery, University Hospital Heidelberg, Heidelberg, Germany (Dr. V. Shavlokhova)


[CLICK HERE](#)

 PMID: 32418329
(2020)

99% specificity and 88% sensitivity

Application	BCC subtypes
Study design	78 BCCs 78 patients
Microscope generation	G4
Clinical partner (principal investigator)	Dept. of Dermatology, Hospital Clinic of Barcelona, IDIBAPS, University of Barcelona, Barcelona, Spain (Dr. J. Malvehy & Dr. J. Perez-Anker)


[CLICK HERE](#)

 PMID: 31220341
(2020)

Inflammatory patterns were very well distinguished e.g. infiltrated lymphocytes and neutrophils

Application	Inflammatory skin disease
Study design	6 mm punch biopsies 33 patients
Microscope generation	G4
Clinical partner (principal investigator)	Dept. of Dermatology, Venereology and Allergology, University of Leipzig, Leipzig, Germany (Dr. S. Grunewald & J. Mentzel)


[CLICK HERE](#)

 PMID: 33085808
(2020)

Dermatology > Skin

Histomorphological and immunofluorescence features of PV were detected simultaneously in one imaging session

Application	Pemphigus Vulgaris
Study design	20 Pemphigus Vulgaris sections
Microscope generation	G4
Clinical partner (principal investigator)	Dept. of Dermatology and Allergy, University Hospital, LMU Munich, Munich, Germany (Dr. Hartmann)


[CLICK HERE](#)

 PMID: 33491324
(2021)
Distinguished almost all skin morphological features in a pilot study

Application	Normal morphology
Study design	26 healthy skins
Microscope generation	G4
Clinical partner (principal investigator)	Dept. of Dermatology, Venereology and Allergology, University Hospital Leipzig AoER, Leipzig, Germany (Dr. S. Grunewald)


[CLICK HERE](#)

 PMID: 31732988
(2020)

Dermatology > Nail

91.7% specificity and 90.5% negative predicted value

Application	Onychomycosis
Study design	57 patients
Microscope generation	G4
Clinical partner (principal investigator)	Dept. of Dermatology and Allergy, University Hospital, LMU Munich, Munich, Germany (Dr. Hartmann)


[CLICK HERE](#)

 PMID: 33240908
(2020)

Urology > Prostate

100% specificity and 79% sensitivity

Application	Biopsy
Study design	121 MRI-fused prostate biopsy samples 10 patients
Microscope generation	G4
Clinical partner (principal investigator)	Dept. of Pathology, Klinikum Lippe GmbH, Detmold, Germany (Ulf Titze, Torsten Hansen & Prof. K. Sievert)


[CLICK HERE](#)

 PMID: 33816171
(2021)
93.5% specificity and 83.3% sensitivity

Application	Biopsy
Study design	89 samples 13 patients
Microscope generation	G4
Clinical partner (principal investigator)	Dept. of Urology, University of Modena and Reggio Emilia, Modena, Italy (Prof. G. Bianchi, Prof. R. Montironi & Prof. B. Rocco)


[CLICK HERE](#)

 PMID: 30908852
(2019)
97.5% specificity and 88% sensitivity

Application	Biopsy
Study design	80 biopsies of 18-G thickness
Microscope generation	G4
Clinical partner (principal investigator)	Dept. of Surgical, Medical, Dental and Morphological Sciences with Interest transplant, Oncological and Regenerative Medicine, University of Modena and Reggio Emilia, Modena, Italy (Prof. R. Montironi & Prof. B. Rocco)


[CLICK HERE](#)

 PMID: 31907606
(2020)
81% Cohen's K agreement

Application	Biopsy
Study design	182 MRI-guided core biopsies 57 patients
Microscope generation	G4
Clinical partner (principal investigator)	Dept. of Urology, Fundacion Instituto Valenciano de Oncologia, Valencia, Spain (Dr. A. Calatrava, J. Casanova & Dr. Jose Rubio)


[CLICK HERE](#)

 PMID: 32912840
(2020)
Cohen's K agreement was 94% for fatty tissue and 97.14% for muscular/vascular tissues

Application	Margin control
Study design	41 prostate margins 20 patients
Microscope generation	G4
Clinical partner (principal investigator)	Dept. of Urology, University of Modena and Reggio Emilia, Modena, Italy (Prof. R. Montironi & Prof. B. Rocco)


[CLICK HERE](#)

 PMID: 31971342
(2020)
97.2% specificity and 86.3% sensitivity

Application	Biopsy
Study design	427 core biopsies 54 patients
Microscope generation	G4
Clinical partner (principal investigator)	Dept. of Urology, University of Modena and Reggio Emilia, Modena, Italy (Prof. R. Montironi & Prof. B. Rocco)


[CLICK HERE](#)

 PMID: 32952095
(2020)
A novel approach to evaluate prostate margins

Application	Margin control
Study design	8 prostate margins
Microscope generation	G4
Clinical partner (principal investigator)	Dept. of Urology, University of Modena and Reggio Emilia, Modena, Italy (Prof. R. Montironi & Prof. B. Rocco)


[CLICK HERE](#)

 PMID: 32401370
(2020)
The real-time pathology of core biopsies potentially reduces disease recurrence and functional complications

Application	Cryotherapy
Study design	MRI-fused core biopsies 10 patients
Microscope generation	G4
Clinical partner (principal investigator)	Dept. of Urology and Renal Transplantation, University of Foggia, Foggia, Italy (Dr. O. Selvaggio, Prof. G. Carrieri)


[CLICK HERE](#)

 Posater MP46-14
(2021)

Urology > Kidney

K agreement was strong (1 to 0.97) for most tissue compartments

Application	Biopsy
Study design	24 renal autopsies were sampled with spring-loaded biopsy device
Microscope generation	G4
Clinical partner (principal investigator)	Nephrology and Renal Transplantation Dept., Hospital Clinic of Barcelona, University of Barcelona, Barcelona, Spain (Dr. J. Malveyh & Dr. A Garcia-Herrera)



[CLICK HERE](#)

more information

PMID: 32876939
(2020)

Detection of tumor and normal tissue in 100% of cases

Application	Biopsy
Study design	8 ultrasound-guided core biopsies 4 patients
Microscope generation	G4
Clinical partner (principal investigator)	Dept. of Urology, Fundacion Instituto Valenciano Oncologia, Valencia, Spain (M Carmen Mir, Dr. A. Calatrava & Dr. J. Rubio)



[CLICK HERE](#)

more information

PMID: 31833726
(2020)

Urology > Bladder

High sensitivity and specificity in agreement with the final histopathologic images

Application	TURBT
Study design	50 TUR-bladder
Microscope generation	G4
Clinical partner (principal investigator)	Asklepios Clinic Barbek, Dept. of Urology, Hamburg, Germany (Dr. C. Netsch)



[CLICK HERE](#)

more information

Nord-congress of urology
HF- 12-03 (2020)

Urology > Bladder & ureter

100% agreement

Application	TURBT & flexible-URS
Study design	5 bladder and 1 ureter samples 4 patients
Microscope generation	G4
Clinical partner (principal investigator)	Dept. of Urology, University of Modena and Reggio Emilia, Modena, Italy (Dr. S. Puliatti, Prof. G. Bianchi, Prof. B. Rocco)



[CLICK HERE](#)

more information

34th annual EAU congress
(2019)

Gastroenterology > Intestine

Immediate diagnosis of tubular adenoma with high-grade dysplasia

Application	Endoscopic biopsy
Study design	Case report
Microscope generation	G4
Clinical partner (principal investigator)	Melanoma Unit, Dept. of Dermatology, Hospital Clinic of Barcelona, IDIBAPS, University of Barcelona, Barcelona, Spain (Dr. J. Malvehy & Dr. Miriam Cuatrecasas)



[CLICK HERE](#)

more information

PMID: 32376329
(2020)

Tubular adenoma: 84% specificity and 95% sensitivity serrated sessile lesion: 96% specificity and 69.5% sensitivity

Application	Endoscopic biopsy
Study design	36 polyps
Microscope generation	G4
Clinical partner (principal investigator)	Endoscopy Unit, Dept. Of Gastroenterology, Hospital Clinic of Barcelona, IDIBAPS, University of Barcelona, Barcelona, Spain (Dr. J. Malvehy & Dr. Miriam Cuatrecasas)



[CLICK HERE](#)

more information

Gastrointestinal Endoscopy
Mo1653 (2020)

Gastroenterology > Pancreas

Rapid evaluation of EUS fine-needle biopsy sampling in pancreatic solid lesions: Cohen's K agreement was 95% and 100% sensitivity

Application	Biopsy & CytoMatrix
Study design	EUS-Fine Needle Biopsy samples 81 patients
Microscope generation	G4
Clinical partner (principal investigator)	Dept of Operative Endoscopy, Campus Bio-Medico University Hospital, Rome, Italy (Dr. Anna Crescenzi & Dr. F. M. Di Matteo)



[CLICK HERE](#)

more information

PMID: 33798539
(2021)

Multiple > Multiple

97.3% specificity and 91.6% sensitivity

Application	IR-guided needle biopsy
Study design	105 core needle biopsies 105 patients
Microscope generation	G4
Clinical partner (principal investigator)	Division of Pathology and Laboratory Medicine, The University of Texas MD Anderson Cancer Center, Houston, USA (Dr. S. Krishnamurthy & Prof. S. Gupta)



[CLICK HERE](#)

more information

PMID: 32134465
(2020)

97.3% specificity and 95.5% sensitivity

Application	Margin control
Study design	118 surgical specimens
Microscope generation	Prototype G4
Clinical partner (principal investigator)	Division of Pathology and Laboratory Medicine, The University of Texas MD Anderson Cancer Center, Houston, USA (Dr. S. Krishnamurthy & Prof. S. Gupta)



[CLICK HERE](#)

more information

PMID: 30376375
(2018)

Selected clinical studies using VivaScope 2500 microscope¹

Organ	Application	Study results vs. the final histology reports	Study design	Microscope generation	Clinical partner (principal investigator)	PubMed link (year) (PubMed ID: PMID)
Skin	Review	Revolution in fast pathology in dermatology	A comprehensive review of 79 publications	G4-G3	Dept. of Dermatology, Hospital Clinic of Barcelona, IDIBAPS, University of Barcelona, Barcelona, Spain (Dr. S. Puig & Dr. J. Malvehy)	PMID: 32134506 (2020)
	BCC margin control	96.5% specificity and 73.6% sensitivity	101 BCCs 78 patients	G4	Dept. of Dermatology, Venereology and Allergology, University Hospital Leipzig AoER, Leipzig, Germany (Dr. S. Grunewald)	PMID: 33768732 (2021)
	BCC margin control	91% specificity and 92% sensitivity	46 frozen sections of BCCs	G4	Dept. of Dermatology and Allergy, University Hospital, LMU Munich, Munich, Germany (Dr. Hartmann)	PMID: 33991061 (2021)
	Oral leukoplakia	92.3% specificity and 96.3% sensitivity	27 oral lesions 22 patients	G4	Dept. of Oral and Maxillofacial Surgery, University Hospital Heidelberg, Heidelberg, Germany (Dr. V. Shavlokhova)	PMID: 34073373 (2021)
	Oral squamous cell carcinomas (OSCCs)	High potential in rapid diagnosis and evaluation of the fresh excised OSCCs	38 OSCCs 35 patients	G4	Dept. of Oral and Maxillofacial Surgery, University Hospital Heidelberg, Heidelberg, Germany (Dr. V. Shavlokhova)	PMID: 33368199 (2021)
	Oral squamous cell carcinomas (OSCCs)	95% specificity and 99% sensitivity	70 oral lesions 70 patients	G4	Dept. of Oral and Maxillofacial Surgery, University Hospital Heidelberg, Heidelberg, Germany (Dr. V. Shavlokhova)	PMID: 32418329 (2020)
	BCC subtypes	99% specificity and 88% sensitivity	78 BCCs 78 patients	G4	Dept. of Dermatology, Hospital Clinic of Barcelona, IDIBAPS, University of Barcelona, Barcelona, Spain (Dr. J. Malvehy & Dr. J. Perez-Anker)	PMID: 31220341 (2020)
	Inflammatory skin disease	Inflammatory patterns were very well distinguished e.g. infiltrated lymphocytes and neutrophils	6-mm punch biopsies 33 patients	G4	Dept. of Dermatology, Venereology and Allergology, University of Leipzig, Leipzig, Germany (Dr. S. Grunewald & J. Mentzel)	PMID: 33085808 (2020)
	Pemphigus Vulgaris	Histomorphological and immunofluorescence features of PV were detected simultaneously in one imaging session	20 Pemphigus Vulgaris sections	G4	Dept. of Dermatology and Allergy, University Hospital, LMU Munich, Munich, Germany (Dr. Hartmann)	PMID: 33491324 (2021)
	Normal morphology	Distinguished almost all skin morphological features	26 healthy skins	G4	Dept. of Dermatology, Venereology and Allergology, University Hospital Leipzig AoER, Leipzig, Germany (Dr. S. Grunewald)	PMID: 31732988 (2020)
Nail	Onychomycosis	91.7% specificity and 90.5% negative predicted value	57 patients	G4	Dept. of Dermatology and Allergy, University Hospital, LMU Munich, Munich, Germany (Dr. Hartmann)	PMID: 33240908 (2020)

Prostate	Biopsy	100% specificity and 79% sensitivity	121 MRI-fused prostate biopsies 10 patients	G4	Dept. of Pathology, Klinikum Lippe GmbH, Detmold, Germany (Ulf Titze, Torsten Hansen & Prof. K. Sievert)	PMID: 33816171 (2021)
	Biopsy	93.5% specificity and 83.3% sensitivity	89 punch biopsies of 18-G thickness 13 patients	G4	Dept. of Urology, University of Modena and Reggio Emilia, Modena, Italy (Prof. G. Bianchi, Prof. R. Montironi & Prof. B. Rocco)	PMID: 30908852 (2019)
	Cryotherapy	The real-time pathology of core biopsies potentially reduces disease recurrence and functional complications	MRI-fused core biopsies 10 patients	G4	Dept. of Urology and Renal Transplantation, University of Foggia, Foggia, Italy (Dr. O. Selvaggio, Prof. G. Carrieri)	Posater MP46-14 (2021)
	Biopsy	97.5% specificity and 88% sensitivity	80 biopsies of 18-G thickness	G4	Dept. of Surgical, Medical, Dental and Morphological Sciences with Interest transplant, Oncological and Regenerative Medicine, University of Modena and Reggio Emilia, Modena, Italy (Prof. R. Montironi & Prof. B. Rocco)	PMID: 31907606 (2020)
	Biopsy	81% Cohen's K agreement	182 MRI-guided core biopsies 57 patients	G4	Dept. of Urology, Fundacion Instituto Valenciano de Oncologia, Valencia, Spain (Dr. A. Calatrava, J. Casanova & Dr. Jose Rubio)	PMID: 32912840 (2020)
	Margin control	Cohen's K agreement was 94% for fatty tissue and 97.14% for muscular/vascular tissues	41 prostate margins 20 patients	G4	Dept. of Urology, University of Modena and Reggio Emilia, Modena, Italy (Prof. R. Montironi & Prof. B. Rocco)	PMID: 31971342 (2020)
	Biopsy	97.2% specificity and 86.3% sensitivity	427 core biopsies 54 patients	G4	Dept. of Urology, University of Modena and Reggio Emilia, Modena, Italy (Prof. R. Montironi & Prof. B. Rocco)	PMID: 32952095 (2020)
	Margin control	A novel approach to evaluate prostate margins	8 prostate margins	G4	Dept. of Urology, University of Modena and Reggio Emilia, Modena, Italy (Prof. R. Montironi & Prof. B. Rocco)	PMID: 32401370 (2020)
Kidney	Biopsy	K agreement was strong (1 to 0.97) for most tissue compartments	24 renal autopsies were sampled with spring-loaded biopsy device	G4	Nephrology and Renal Transplantation Dept., Hospital Clinic of Barcelona, University of Barcelona, Barcelona, Spain (Dr. J. Malveyh & Dr. A Garcia-Herrera)	PMID: 32876939 (2020)
	Biopsy	Detection of tumor and normal tissue in 100% of cases	8 ultrasound-guided core biopsies 4 patients	G4	Dept. of Urology, Fundacion Instituto Valenciano Oncologia, Valencia, Spain (M Carmen Mir, Dr. A. Calatrava & Dr. J. Rubio)	PMID: 31833726 (2020)
Bladder & ureter	TURBT & flexible-URS	100% agreement	5 bladder and 1 ureter samples 4 patients	G4	Dept. of Urology, University of Modena and Reggio Emilia, Modena, Italy (Dr. S. Puliatti, Prof. G. Bianchi, Prof. B. Rocco)	34th annual EAU congress (2019)
Bladder	TURBT	High sensitivity and specificity in agreement with the final histopathologic images	50 TUR-bladder	G4	Asklepios Clinic Barbek, Dept. of Urology, Hamburg, Germany (Dr. C. Netsch)	Nord-congress of urology HF 12-03 (2020)
Pancreas	Biopsy & CytoMatrix	Cohen's K agreement was 95% 100% sensitivity	EUS-Fine Needle Biopsy samples 81 patients	G4	Dept of Operative Endoscopy, Campus Bio-Medico University Hospital, Rome, Italy (Dr. Anna Crescenzi & Dr. F. M. Di Matteo)	PMID: 33798539 (2021)
Intestine	Endoscopic biopsy	Tubular adenoma: 84% specificity and 95% sensitivity serrated sessile lesion: 96% specificity and 69.5% sensitivity	36 polyps	G4	Endoscopy Unit, Dept. Of Gastroenterology, Hospital Clinic of Barcelona, IDIBAPS, University of Barcelona, Barcelona, Spain (Dr. J. Malveyh & Dr. Miriam Cuatrecasas)	Gastrointestinal Endoscopy Mo1653 (2020)
	Endoscopic biopsy	Immediate diagnosis of tubular adenoma with high-grade dysplasia	Case report	G4	Melanoma Unit, Dept. of Dermatology, Hospital Clinic of Barcelona, IDIBAPS, University of Barcelona, Barcelona, Spain (Dr. J. Malveyh & Dr. Miriam Cuatrecasas)	PMID: 32376329 (2020)

Multiple ²	IR-guided ² needle biopsy	97.3% specificity and 91.6% sensitivity	105 core needle biopsies ² 105 patients	G4	Division of Pathology and Laboratory Medicine, The University of Texas MD Anderson Cancer Center, Houston, USA (Prof S. Krishnamurthy & Prof. S. Gupta)	PMID: 32134465 (2020)
Multiple ³	Margin control	97.3% specificity and 95,5% sensitivity	118 surgical specimens	Prototype G4	Division of Pathology and Laboratory Medicine, The University of Texas MD Anderson Cancer Center, Houston, USA (Prof. S. Krishnamurthy & Prof. S. Gupta)	PMID: 30376375 (2018)
Generation 3 of the VivaScope 2500 microscope (G3) was the old version and provided only black & white images. Generation 4 (G4) is 4 times faster and provides pseudo-color H&E-like digital images.						
Skin	BCC margin control	95.8% specificity and 79.8% sensitivity	127 BCCs 127 patients	G3	Dept. of Dermatology, University of Modena and Reggio Emilia, Modena, Italy (Dr. C. Longo, Dr. M. Ragazzi & Prof. G. Pellacani)	PMID: 30512198 (2019)
	BCC margin control	98.7% specificity and 96.6% sensitivity	235 skin samples 150 patients	G3	Dept. of Dermatology and Allergy, University Hospital, LMU Munich, Munich, Germany (Dr. D. Hartmann & Dr. T. V. Braunmuehl)	PMID: 29726112 (2018)
	SCC margin control	Tumor features were well matched (χ^2 analysis) to H&E images for the diagnosis of invasive SCC	102 SCC 57 patients	G3	Dept. of Dermatology and Allergy, University Hospital, LMU Munich, Munich, Germany (Dr. D. Hartmann & Dr. T. V. Braunmuehl)	PMID: 29227042 (2018)
	SCC margin control	Margin assessment agreed in 41 of 43 mosaics	34 tumor margins 13 patients	G3	Skin Cancer Unit, IRCSS Santa Maria Nuova Hospital, Reggio Emilia, Italy (Dr. C. Longo & Prof. G. Pellacani)	PMID: 26183978 (2015)
	BCC margin control	100% specificity and 100% sensitivity	42 BCCs 41 patients	G3	Dept. of Ophthalmology, University Hospital of St-Etienne, Saint Etienne, France (Dr. E. Cinotti & Dr. J. Luc Perrot)	PMID: 27990744 (2017)
	BCC & SCCs margin control	99% specificity and 93% sensitivity	64 BCC and SCC 74 patients	G3	The Ronald O. Perelman Dept. of Dermatology, New York University School of Medicine, New York, USA (Dr. Daniel S. Gareau)	PMID: 27603676 (2016)
	Normal morphology	Distinguished skin morphological features in a pilot study	50 healthy skins	G3	Dept. of Dermatology and Allergy, University Hospital, LMU Munich, Munich, Germany (Dr. D. Hartmann & Dr. T. V. Braunmuehl)	PMID: 25996548 (2016)
	Melanocytic lesions	Successfully distinguished the main melanocytic features of lesions in a pilot study	31 melanocytic lesions	G3	Dept. of Dermatology and Allergy, University Hospital, LMU Munich, Munich, Germany (Dr. D. Hartmann & Dr. T. V. Braunmuehl)	PMID: 27091702 (2017)
	Cutaneous inflammation	Successfully distinguished the main inflammatory features of lesions in a pilot study	147 cutaneous lesions	G3	Dept. of Surgical, Medical, Dental and Morphological Sciences with Interest transplant, Oncological and Regenerative Medicine, University of Modena and Reggio Emilia, Modena, Italy (Dr. C. Longo & Prof. G. Pellacani)	PMID: 30033578 (2018)
	BCC margin control	99% specificity and 88% sensitivity	80 BCCs 74 patients	G3	Melanoma Unit, Dept. of Dermatology, Hospital Clinic of Barcelona, IDIBAPS, University of Barcelona, Barcelona, Spain (Dr. A. Bennisar & Dr. J. Malvehy)	PMID: 24117457 (2014)
BCC margin control	The study classified BCC subtypes with an overall agreement ⁴ of $\kappa=0.9$	69 BCCs 66 patients	G3	Dept. of Dermatology, Hospital Clinic of Barcelona, IDIBAPS, University of Barcelona, Barcelona, Spain (Dr. A. Bennisar & Dr. J. Malvehy)	PMID: 23636776 (2013)	
Breast	Margin control & biopsy	93% specificity and 93% sensitivity	70 samples 31 patients	G3	Rice University, Department of Bioengineering, 6500 Main Street, BRC 502, Houston, Texas 77030, USA (Jessica L Dobbs & Rebecca Richards-Kortum)	PMID: 24165742 (2013)

Brain	Margin control & biopsy	recognised tumor features quickly without tissue loss in a pilot study	20 samples 19 patients	G3	Dept. of Pathology, University Hospital of Saint Etienne, North Hospital, Saint Etienne CEDEX 2, France (Dr. F. Forest, J.L. Perrot & Dr. M. Peoch)	PMID: 26033548 (2015)
Brain	Biopsy	Diagnosed the brain aspergillosis Ex Vivo & rapidly in a pilot study	Case report	G3	Dept. of Pathology, University Hospital of Saint Etienne, North Hospital, Saint Etienne CEDEX 2, France (Dr. F. Forest, J.L. Perrot & Dr. M. Peoch)	PMID: 26126596 (2016)
Multiple ⁵	Margin control & lymph node	The images of the pilot study were as accurate as the conventional histology	35 samples 30 patients	G3	Pathology Unit, IRCSS Santa Maria Nuova Hospital, Reggio Emilia, Italy (Dr. C. Longo, Dr. M. Ragazzi & Prof. G. Pellacani)	PMID: 24030744 (2014)

1) [Click here](#) for the full list of publications.

2) Interventional radiology (IR)-guided core-needle biopsies from bone, kidney, liver, lung, lymph node, pleura and soft tissues.

3) Imaged 118 tissue fragments from surgical excision specimens: 40 breast, 23 lung, 39 kidney, and 16 liver.

4) For example: the palisading criteria (n=138) had 100% Sp & 96% Se for surrounding dermis; 96% Sp & 96% Se for hair follicles and 91% Sp & 96% Se for Eccrine gland cells.

5) Imaged 12 breast lumpectomies, 8 thyroids, 7 colorectal resections and 8 lymph nodes (6 axillary and 2 cervical lymph nodes)